

Case Report

Pancreatic window and open necrosectomy; a surgical alternative for walled-off pancreatic necrosis in a second level hospital in Mexico

Pedro A. Alvarado-Bahena, Enrique Chávez-Serna*, Jonathan Salgado-Vives,
Uraik F. Hernández-Bustos, Dante A. Saldivar-Vera, Landy L. Mendoza-Morales,
Pedro A. Espinosa de los Monteros-Moranchel

Department of General Surgery, Regional General Hospital, Mexican Institute of Social Security, Queretaro, México

Received: 28 August 2020

Revised: 30 September 2020

Accepted: 09 October 2020

*Correspondence:

Dr. Enrique Chávez-Serna,

E-mail: chavez.serna@gmail.com

Copyright: © the author(s), publisher and licensee Medip Academy. This is an open-access article distributed under the terms of the Creative Commons Attribution Non-Commercial License, which permits unrestricted non-commercial use, distribution, and reproduction in any medium, provided the original work is properly cited.

ABSTRACT

Walled-off pancreatic necrosis is defined as a necrotic collection with a defined wall, which generally occurs in 15% of patients in the fourth week after acute pancreatitis. Actually, open surgery is reserved for selected cases, with minimally invasive treatments such as image-assisted percutaneous drainage or endoscopic ultrasound being the procedures of choice. However, in developing countries the open approach continues to be an effective therapeutic alternative. We present the case of a 47-year-old male patient with no significant history who developed severe acute pancreatitis secondary to hypertriglyceridemia and who later developed walled-off pancreatic necrosis as a late complication. As a treatment, a debridement of the necrotic tissue with marsupialization was performed using the bradley III technique, secondary to the procedure, a pancreatic fistula was developed. After 8 weeks of hospitalization, in which he had a favourable response to surgical treatment, with spontaneous closure of the fistula without complications. Surgical management of late complications of acute pancreatitis remains controversial. Although minimally invasive procedures are the first option nowadays, in developing countries, open necrosectomy remains a good option for the treatment of these types of complications.

Keywords: Acute pancreatitis, Pancreatic necrosis, Acute necrotizing, Surgery, Disconnected pancreatic duct syndrome, Hypertriglyceridemia

INTRODUCTION

Walled-off pancreatic necrosis is defined as a necrotic collection with a defined wall, which occurs in 15% of patients at least 4 weeks after severe pancreatitis.¹⁻³ Approximately 50% of the patients will be asymptomatic and have a spontaneous resolution of the collection.⁴ Unfortunately the rest of the patients will develop refractory abdominal pain, anorexia, weight loss and poor general condition, which persists for more than 8 weeks after acute pancreatitis and in most cases surgical treatment will be necessary.⁵

The main cause of acute pancreatitis worldwide continues to be of biliary origin (40-70%) followed by alcohol (25-35%). Primary and secondary hypertriglyceridemia only represent 1 to 4% and the risk increases significantly when this exceeds 1000 mg/dl.⁶ Triglycerides themselves do not appear to be toxic. Rather, it is the breakdown of triglycerides into toxic free fatty acids (FFA) by pancreatic lipases that is the cause of lipotoxicity during acute pancreatitis. Severe hypertriglyceridemia plus high lipase levels (>3 times the upper limit of normal) are associated with very high FFA levels and can further be complicated by systemic inflammation from acute

pancreatitis, direct activation of toll-like receptor (TLR)-2 and TLR4 by FFA, and direct lipotoxicity.⁷

For the diagnosis of a pancreatic complication, computerized axial tomography (CT) and magnetic resonance imaging (MRI) continue to be the studies of choice, with CT with contrast being the first option due to its cost-availability ratio in hospital centers. Currently, open surgery is reserved for selected cases, with minimally invasive treatments (image-assisted percutaneous drainage, endoscopic ultrasound) being the procedures of choice for the approach to complications of the pancreas. However, in developing countries, where resources are limited, the open approach continues to be an effective therapeutic alternative.⁸ Open surgery is associated with a high risk of complications such as mortality from 34% to 95%, and chronic pancreatic insufficiency ranging from 11% to 39%.⁶

CASE REPORT

We present the clinical case of a 47-year-old male patient admitted to the emergency department of a regional hospital in Mexico, due to severe acute pancreatitis secondary to hypertriglyceridemia in October 2019, after 30 days of hospital stay, his discharge was decided due to clinical improvement, however, presented two new events of mild pancreatitis (December 2019 and March 2020) that did not require surgical treatment.

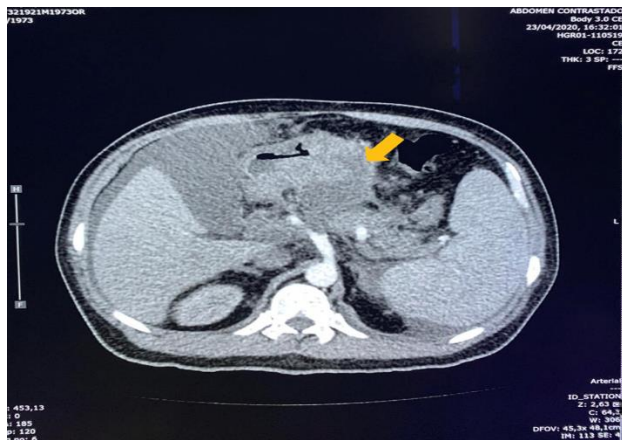


Figure 1: Preoperative abdominal CT with IV contrast, showing the liquid collection area with dimensions of 56×42 mm adjacent to the head of the pancreas.

In April 2020, he was admitted to our hospital unit with the following clinical presentation: vomiting, nausea, intolerance to the oral route, transfictional epigastric pain, irradiated to the interscapular area, and systemic inflammatory response. Given the history, a double contrast abdominal CT scan was performed where the following was described (Figure 1), pancreas of normal location, enlarged in dimensions, irregular borders not clearly defined, after the application of contrast in the arterial phase showed a heterogeneous enhancement in

the head of the pancreas in addition to a liquid collection with dimensions of 56×42 mm adjacent to the head of the pancreas. Due to the clinical and imaging characteristics, a walled-off pancreatic necrosis was suspected, probably infected, so invasive treatment is decided as we do not have minimally invasive procedures in our hospital.

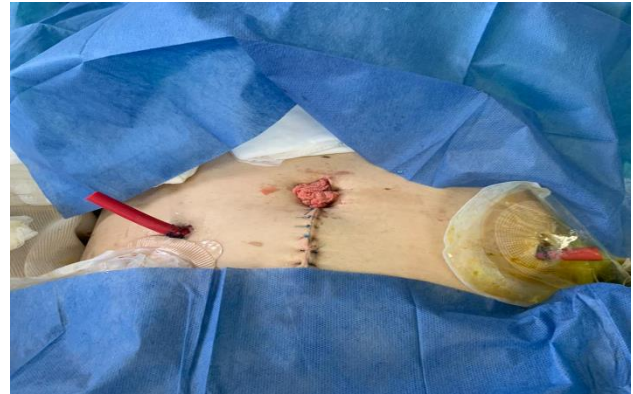


Figure 2: Marsupialized pancreatic window with both drains. Right drainage between the body and tail of the pancreas externalized to the right flank. Left drainage in the head of the pancreas exteriorized on the left flank.

Next, the open necrosectomy was performed with the bradley III technique, a supra and infra umbilical incision was made, the mesocolon and the gastrocolic ligament were identified and through these a dissection was performed to address the pancreas, the necrotic tissue was identified and later a digital necrosectomy was performed, leaving only the firmly adhered tissue, hemostasis of the bleeding area with transfictional points was performed, 60 ml of purulent fluid and 30 grams of necrotic pancreatic tissue were drained. Two 14 french (Fr) nelaton-type drainage catheters were placed for daily irrigation with 30 ml of sterile solution (Figure 2). The right drain was placed between the body and tail of the pancreas through the gastrocolic ligament and the left drain was placed in the head of the pancreas through the transverse mesocolon; finally, a pancreatic window was created in the proximal third of the surgical wound by placing sterile gauze pads in order to move the stomach cephalad and the transverse colon caudally in such a way that the lesser sac would be in communication with the outside with the intention of carrying out serial irrigations 48 to 72 hours later if necessary. Post-surgical medical management was based on parenteral nutrition, octreotide (somatostatin analog), proton pump inhibitors and broad-spectrum antibiotics (carbapenems). Course with drainage initially quantified in 70 ml per day with ochre characteristics, with progressive decrease during hospital stay. Fifteen days after the surgical event, an oral diet was started with an adequate response to it, closure of the spontaneous pancreatic fistula and closure of the wound by second intention, a double contrast control tomography was performed prior to his discharge at 8 weeks, where the following was reported; little visible

atrophic pancreas, of homogeneous density, without space-occupying lesions at this level at the time of the study, with increased density in the peri-pancreatic abdominal fat without defined collections (Figure 3). All computed tomography scans were performed with a multislice technique with 3-mm reconstructions and with contrast in the arterial phase.

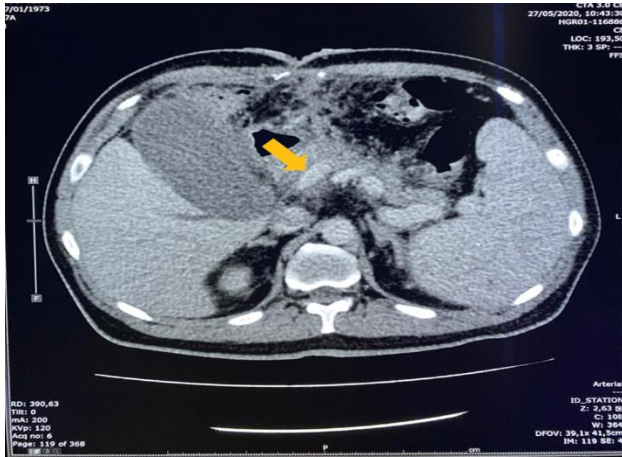


Figure 2: Postoperative abdominal CT with IV contrast, it is indicated where atrophic pancreas is observed, without collections.

DISCUSSION

According to the Atlanta classification, complications of acute pancreatitis are divided into early, before 4 weeks (peri-pancreatic edema and acute necrosis) and late after 4 weeks (pancreatic pseudocyst and walled-off pancreatic necrosis, respectively).⁹ Walled-off pancreatic necrosis may involve pancreatic tissue and/or extrapancreatic tissue, it is considered a completely different clinical entity and with a worse prognosis compared to pseudocyst.^{10,11} The pathophysiology of walled-off pancreatic necrosis is still not fully understood, however, it is known that this entity assumes a relationship with pancreatic activity and the extent of damage to pancreatic islet cells, associated with a systemic inflammatory response. It is often said that the time of encapsulation takes about 4 weeks, however in recent studies there was a wide range in the temporality in which necrotic collections were encapsulated. In 85% of patients, it took more than 4 weeks for the necrotic collections to fully form, while in 3 to 12%, the necrosis was already wall-defined seen during the second and third weeks, respectively.^{12,13}

Currently, the treatment of choice for encapsulated necrosis is endoscopic necrosectomy, which according to recent studies has a lower complication rate compared to open necrosectomy, 17% to 20% versus 69% to 80%, respectively.^{13,14} However, in developing countries this type of procedure is only performed in specialized centers or third level of care, which makes them not very accessible and expensive, which is why surgical

procedures are a reliable alternative to these types of complications.⁸ Open necrosectomy consists of debriding all possible necrotic tissue to avoid multiple surgical interventions. Subsequently, several drains can be left through established routes, which can be used for continuous postoperative lavage and for the control of the pancreatic fistula. Open abdomen therapies will facilitate the evacuation of excess intra-abdominal fluid, preventing complications such as compartment syndrome or residual collections. The mean risk of reoperation for incomplete necrosectomy, hemorrhage, or intestinal necrosis is 15%.¹⁵ The risk of pancreatic fistula ranges from 10% to 40%, enteric fistula from 10% to 15%, and incisional hernia from 25% to 50%.¹³ Mortality associated with open necrosectomy is up to 50%. However, in centers with high experience, mortality drops to 5%.¹⁵

CONCLUSION

Surgical management of late complications of acute pancreatitis remains controversial. Although minimally invasive procedures are the first option today, in developing countries, open necrosectomy continues to be an effective alternative treatment. Within the open approaches, necrosectomy with marsupialization and drainage has advantages since it minimizes the damage from possible reoperations, in addition to reducing the risk of residual collections.

Funding: No funding sources

Conflict of interest: None declared

Ethical approval: Not required

REFERENCES

1. Banks PA, Bollen TL, Dervenis C, Gooszen HG, Johnson CD, Sarr MG, et al. Classification of acute pancreatitis—2012. Revision of the Atlanta classification and definitions by international consensus. *Gut*. 2013;62(1):102-11.
2. Driedger M, Zyromski NJ, Visser BC, Jester A, Sutherland FR, Nakeeb A, et al. Surgical transgastric necrosectomy for necrotizing pancreatitis: a single-stage procedure for walled-off pancreatic necrosis. *Anna Surg*. 2020;271(1):163-8.
3. Working Group IAP/APA Acute Pancreatitis Guidelines. IAP/APA evidence-based guidelines for the management of acute pancreatitis. *Pancreatol*. 2013;13(4 Suppl 2):e1-e15.
4. Rana SS. An overview of walled-off pancreatic necrosis for clinicians. *Exp Rev Gastroenterol Hepatol*. 2019;13(4):331-43.
5. Stamatakis M, Stefanaki C, Kontzoglou K, Stergiopoulos S, Giannopoulos G, Safioleas M. Walled-off pancreatic necrosis. *World J Gastroenterol*. 2010;16(14):1707-12.
6. Lowenfels AB, Maisonneuve P, Sullivan T. The changing character of acute pancreatitis:

- epidemiology, etiology, and prognosis. *Curr Gastroenterol Rep.* 2009;11(2):97-103.
7. Yang F, Wang Y, Sternfeld L, Rodriguez JA, Ross C, Hayden MR, et al. The role of free fatty acids, pancreatic lipase and Ca⁺ signalling in injury of isolated acinar cells and pancreatitis model in lipoprotein lipase-deficient mice. *Acta Physiologica (Oxf).* 2009;195(1):13-28.
 8. Ruvalcaba Castañeda OG, Benítez Venegas EV. (2017). *Tratado de Cirugía General. Mexico: Manual Moderno.* Available at: <https://www.amc.org.mx/declaratorias2017/Declaratorias2017.pdf>. Accessed on 02 May 2020.
 9. Van Santvoort HC, Bakker OJ, Bollen TL, Besselink MG, Ali UA, Schrijver AM, et al. A conservative and minimally invasive approach to necrotizing pancreatitis improves outcome. *Gastroenterol.* 2011;141(4):1254-63.
 10. Bradley EL III. A clinically based classification system for acute pancreatitis. Summary of the International Symposium on Acute Pancreatitis, Atlanta, GA, September 11 through 13, 1992. *Arch Surg.* 1993;128:586-90.
 11. Kwong WT, Ondrejková A, Vege SS. Predictors and outcomes of moderately severe acute pancreatitis—evidence to reclassify. *Pancreatol.* 2016;16(6):940-5.
 12. Bakker OJ, van Santvoort H, Besselink MG, Boermeester MA, van Eijck C, Dejong K, et al. Extrapaneatic necrosis without pancreatic parenchymal necrosis: a separate entity in necrotizing pancreatitis?. *Gut.* 2013;62(10):1475-80.
 13. Hollemans RA, Bollen TL, Van Brunschot S, Bakker OJ, Ali UA, Van Goor H, et al. Predicting success of catheter drainage in infected necrotizing pancreatitis. *Annals of surgery.* 2016;263(4):787-92.
 14. Van Santvoort HC, Besselink MG, Bakker OJ, Hofker HS, Boermeester MA, Dejong CH, et al. A step-up approach or open necrosectomy for necrotizing pancreatitis. *New England Journal of Medicine.* 2010;362(16):1491-502.
 15. Bakker OJ, Santvoort HC, Brunschot S, Geskus RB, Besselink MG, Bollen TL, et al. Endoscopic transgastric vs surgical necrosectomy for infected necrotizing pancreatitis: a randomized trial. *J Americ Medic Assoc.* 2012;307(10):1053-61.

Cite this article as: Alvarado-Bahena PA, Chávez-Serna E, Salgado-Vives J, Hernández-Bustos UF, Saldivar-Vera DA, Mendoza-Morales LL, et al. Pancreatic window and open necrosectomy; a surgical alternative for walled-off pancreatic necrosis in a second level hospital in Mexico. *Int J Res Med Sci* 2020;8:xxx-xx.